



# Broken Bridge to Implant-Supported Bridge . . . with No Dentures in Between

By Andrei Mark, D.D.S., Board Certified Oral and Maxillofacial Surgeon

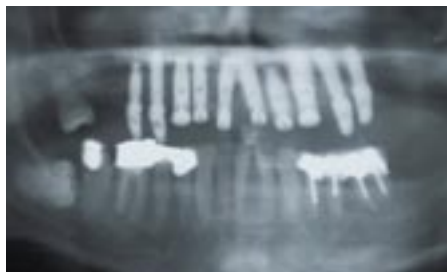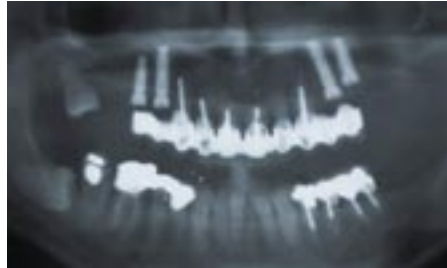
By using the multi-step, interdisciplinary approach a patient can successfully transition from a broken bridge to an implant-supported bridge, without interim dentures. A noteworthy example is the case of Ms. W., a patient in sound health in her mid-50s. This patient was referred to me by her general dentist and she and I collaborated on this case.

The patient arrived for her initial consultation with a loose anterior maxillary 10-unit, cantilevered bridge from 4 through 13 with teeth numbers 6 through 11 as abutments. These abutments were decayed and deemed periodontally and restoratively unsalvageable. A panoramic X-ray of the patient was taken before beginning the procedure. This case occurred just prior to my acquisition of an i-CAT cone beam 3-D imaging system. My protocol today is to take both preoperative and postoperative CT scans. The CT scans provide me with images that project the shape and density of the bone with a true three-dimensional rendering and indicate if any bone grafting is necessary due to resorption.

Given today's dental treatment options, the obvious solution to her problem was dental implants. Dental implants provide the patient with a permanent, stabile solution that will satisfy both her functional and emotional needs, without compromising speech, taste, aesthetics or mastication.

The patient had a couple of concerns. First, she did not want a sinus bone graft. Second, she did not want to wear an interim denture during the implant treatment under any circumstances. Unsure if immediate load could work on this particular case, we opted not to do all the implants at once and elected to go with a two-stage approach.

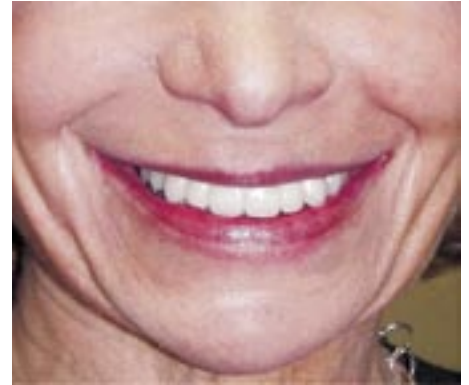At the first surgical visit the loose bridge was removed. Using the bridge as a guide, I



(Top:) Pre-op panoramic.  
(Bottom:) Post-op panoramic

placed Lifecore dental implants in position of teeth numbers 4, 5, 12 and 13, respectively. This case was temporized by re-cementing the existing bridge on the six anterior abutments. At this point, a roundhouse temporary shell was prepared to be used as a temporary, after removing the six anterior teeth and placing six anterior implants. We waited three months to allow for healing and osseointegration to take place.

Three months later at the second surgical visit, the patient arrived for extractions of teeth number 6 through 11 and immediate placement of implants on teeth numbers 6 through 11 using BioLok Silhouette implants. These implants were solid and treated in a single-stage fashion, by placing healing abutments at the same visit. At the same time, the four previously placed implants, numbers 4, 5, 12 and 13, were exposed and temporary crown and bridge abutments were placed to support the new temporary bridge from numbers 4 through 13. The bridge was then relined with cold-cured acrylic and was temporarily cemented with



PHOTOGRAPHY BY JACQUELINE WINTER, D.D.S.

Restorative dentistry by Jacqueline Winter, D.D.S.

retention on numbers 4, 5, 12 and 13 and light vertical rests on the healing screws of teeth numbers 6 through 11. The restoring dentist adjusted the bridge and the occlusion and the patient was dismissed for another three months.

At the six-month point, the patient returned to my office where we removed the temporary bridge, temporary abutments and healing screws and took an implant-level impression. Then everything was replaced and the final impression was sent to Angel Dental Studio. The case was completed by the restoring dentist by placing custom abutments and porcelain fused to metal bridge from teeth numbers 4 through 13.

One could say we envisioned the end result from the very beginning and it served as our guide through the initial steps. True harmony was ultimately achieved because the oral surgeon, the restorative dentist and the lab were in constant communication throughout the entire process.

The patient was very satisfied with her results and happy that she never had to wear an interim denture.

Contact Dr. Andrei Mark at Central Park Oral Surgery, [amark@cpoms.com](mailto:amark@cpoms.com) or by phone at (212) 813-0707. ■