



Overcoming Dental Phobia with Compassion and Results

By Andrei Mark, D.D.S., Board-Certified Oral and Maxillofacial Surgeon

Recently, an 80-year-old man scheduled himself for a dental implant consultation, which was no small task. This was particularly difficult for this patient, because he had become increasingly dental phobic and apprehensive over the years. Ironically, he is the father of someone who works in the dental implant industry, yet he was still very reluctant to make an appointment for a consultation.

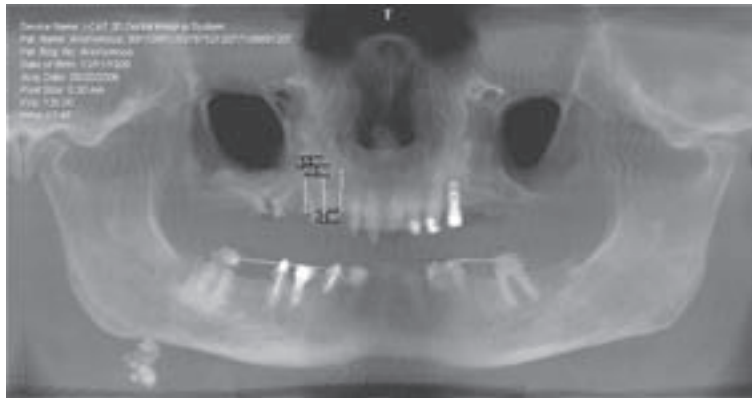
This patient has had a lifetime of dental challenges and difficulties. Contributing to his dental problems were years of both grinding and clenching his teeth. Over time, this patient had developed a dental phobia, predominantly because several of the procedures he had undergone were not performed optimally, and in some cases, actually failed. He had received a great deal of dental “patchwork.”

In his 60s, he began developing chronic abscesses with multiple root canal treatments on his posterior teeth, making them so brittle that they began fracturing. These chronic problems ultimately lead to a collapsed vertical dimension of occlusion. Dentures were not an option, due to a severe gagging condition.

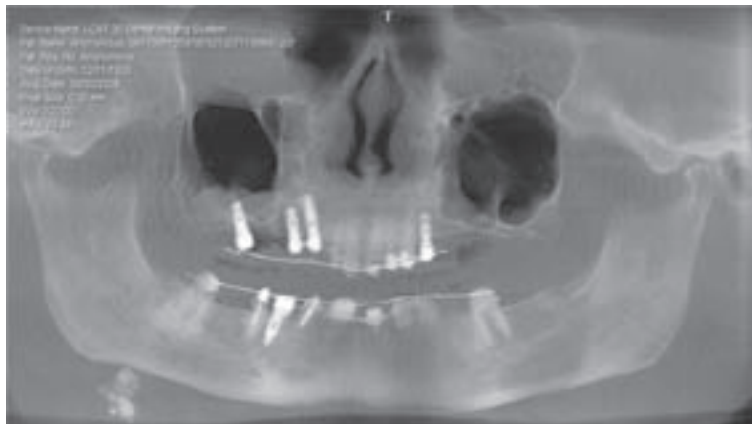Approximately eight years ago, while in his early 70s, the patient received his first dental implants that were placed by another surgeon. When placing the implants in the maxilla, the implant pen-

etrated the sinus and emergency surgery was required to correct the problem.

In aggregate, all of these dental pro-



First Pre-op pano



First Post-op pano

cedures had taken a psychological and emotional toll on this patient. He became extremely self-conscious. He never wanted to go out for dinner because it was too painful, too embarrassing and too uncertain. The patient’s lack of eating resulted in weight loss, with facial contour changes. On top of it all, he had lost his sense of taste as well. His daughter urged him to make an appointment for an implant consultation, and he finally agreed.

As standard protocol, I took a pan-

oramic CT scan to see what had previously been done and understand what I needed to do. From the CT scan I could see that

the patient would ideally require a sinus lift; however, given his concerns and prior history of failed implants, I decided to minimize his anxiety by performing only an internal “pop-up” sinus lift, while simultaneously placing the implants.

I decided to tackle this case using a multi-staged approach, making the procedures less psychologically debilitating for the patient. It was important to treat this apprehensive patient with a great deal of compassion and establish a mutual level of trust.

In past articles, I had written about extractions with immediate-load implants and immediate abutments. Had the patient not been so apprehensive, I would have done immediate-load implants with

immediate abutments for this case as well. However, this case would require a staged approach to put the patient at ease.

After the teeth were extracted, I strategically placed the implants for teeth Nos. 2, 4 and 6, respectively, and the patient was given a long-term, temporary, lab-processed, round-house restoration.

The patient did not return at three-months as planned, but waited six months to return. At that point, I took a CT scan and saw that teeth Nos. 9 and 10 were

non-salvageable. I extracted the root tips of 9 and 10 and placed tapered Lifecore Prima implants. Implants were not immediately loaded, because it was not necessary, since he had a temporary, lab-processed, round-house bridge supported by enough natural teeth.

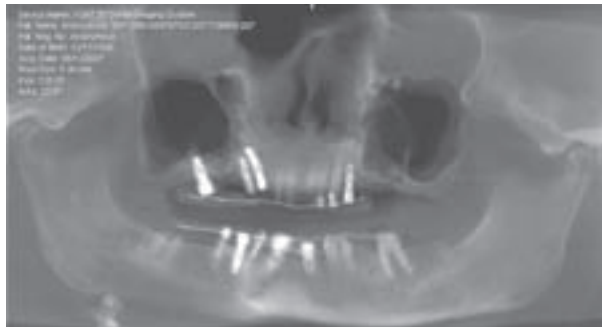By building that level of trust with the patient and treating him with compassion and dignity, I was able to help him overcome his apprehension and his fears. During the second visit to our office, he already seemed much more relaxed and at ease with the process. He said that he didn't realize that he could go through such a procedure without pain and adverse effects.

Based on his emotional state and

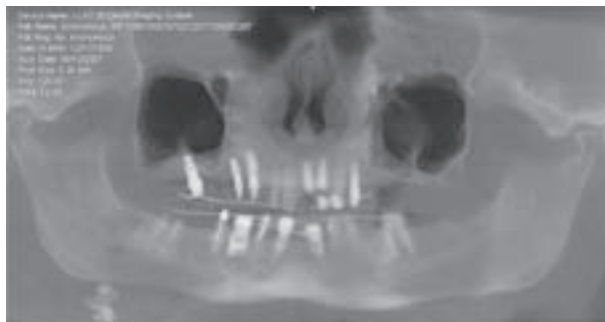collapsed vertical dimension of occlusion, this patient was best restored with long-

term, lab-processed temporaries. Not every patient is a candidate for immediate porcelain-fused-to-metal (PFM) restorations. It is always wise to evaluate the patient's wants and needs. It is OK to maintain more compromised patients with long-term temporaries instead of PFM. It is possible that the patient may desire to transition to a PFM restoration in the future.

Since receiving his dental implants and lab-processed, round-house bridge, the patient has been living life again. His wife says that he is confident in social settings and he is enjoying food once again. His face is no longer sunken and his weight has returned, so he looks happy, healthy and well adjusted. ■



Second Pre-op pano



Second Post-op pano

**SOME OF NEW YORK'S MOST INSPIRING LEADING LADIES
WON'T BE FOUND ON A BROADWAY STAGE.**

**JOIN NEW YORK'S BRIGHTEST
TEACH NYC**

WWW.TEACHNYC.NET



Ad
Council.org

NYC DEPARTMENT OF EDUCATION

Applesseed
FOUNDATION