



# Growing Bone on an Eggshell Sinus, without Harvesting Autologous Bone

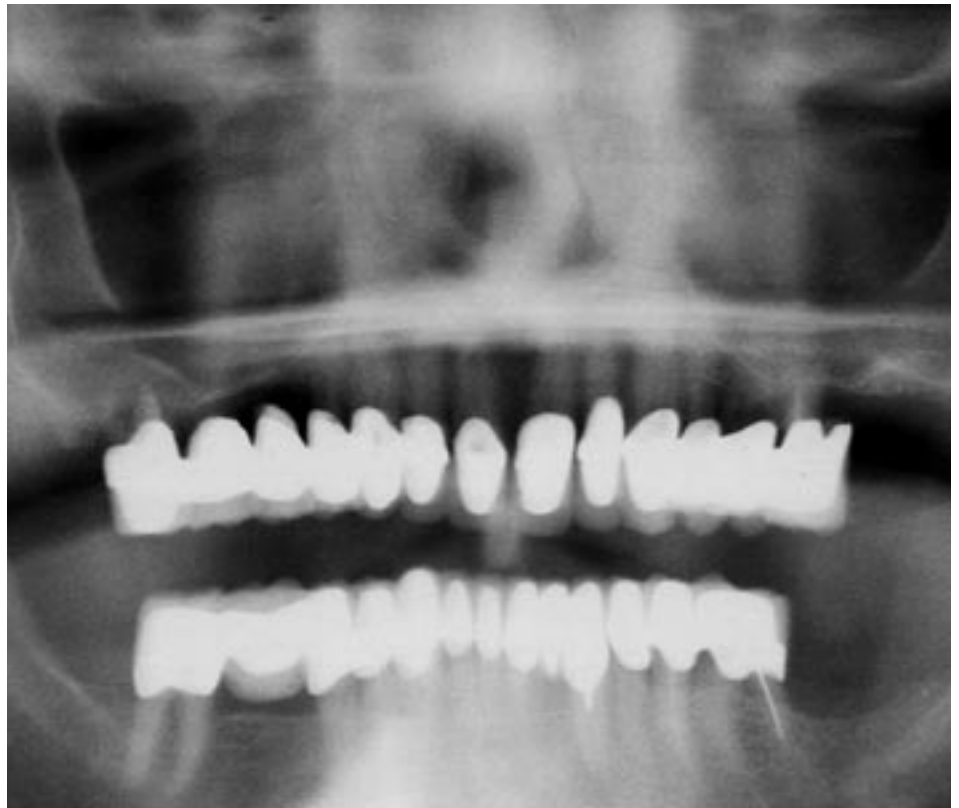By Andrei Mark, D.D.S., Board-Certified Oral & Maxillofacial Surgeon

Several months ago, a patient came to my office for a dental implant consultation. The patient was an 80-year-old male in good physical condition with mild tremors. As protocol, I took CT scans to see exactly what would be required for the patient. (The quality of the CT scans was somewhat affected by the mild tremors of the patient.) The CT scan indicated that the patient had experienced a tremendous amount of resorption, thereby requiring a sinus augmentation. Due to the eggshell thinness of the maxilla, coupled with the patient's age, I was concerned if a conventional sinus lift would work.

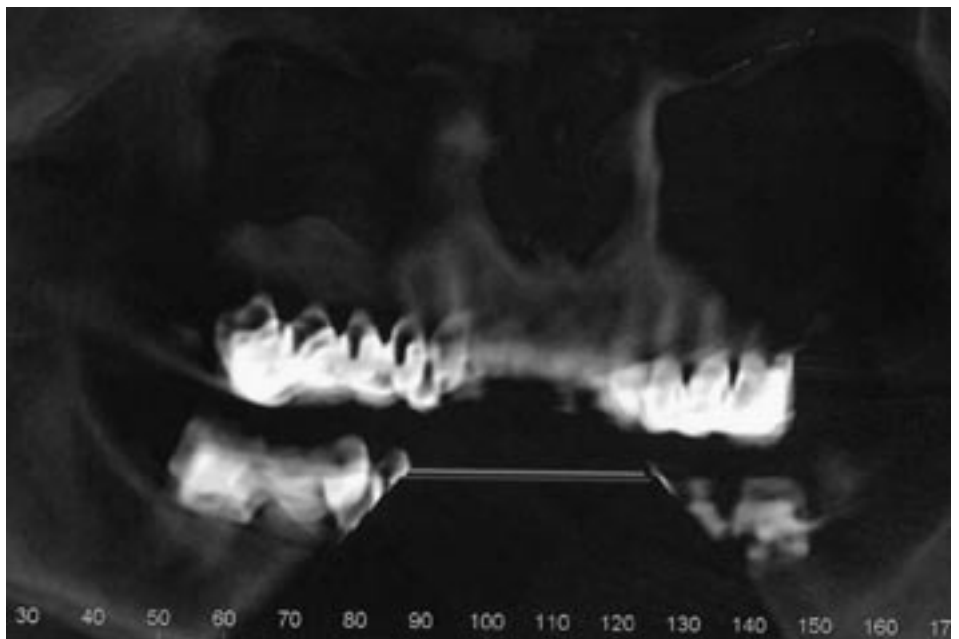
In cases where some residual alveolar bone is left underneath the maxillary sinus, donated cadaver bone and/or other synthetic materials can be used successfully without autologous bone. However, when you have an eggshell residual alveolus, these techniques are less predictable, and may produce undesirable results. These elements are what made this case so interesting and evolutionary.

Given the challenges at hand, it seemed that the patient might be an ideal candidate for a new bone grafting material. INFUSE Bone Graft is recombinant human bone morphogenetic protein-2 (rhBMP-2) applied to an absorbable collagen sponge carrier. The purpose of the protein, which occurs naturally in the human body, is to stimulate bone formation.

The INFUSE Bone Graft product had previously received FDA approval for certain spinal fusion applications and tibial fracture repair procedures.



(Figure a:) Pre-op pano



(Figure b:) Post-op reconstructive CT scan of graft at nine months.

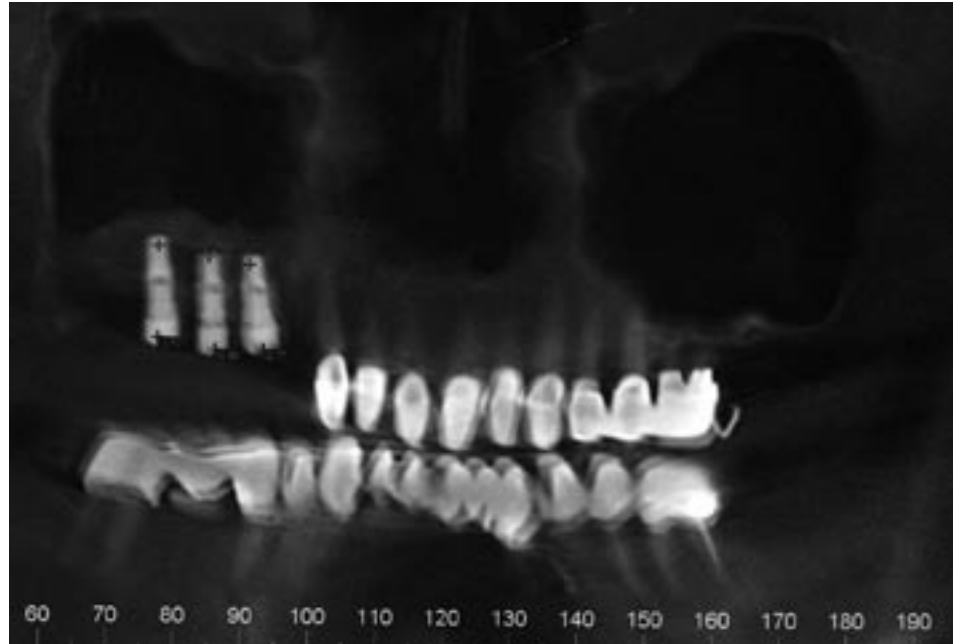
**T**his result can best be categorized as the quality and quantity of bone similar to anterior maxillary bone found in a healthy young adult.

For the past few years, I have been fascinated and very impressed with the clinical research that had been conducted and published regarding this morphogenetic protein-2 (rhBMP-2), and the successes achieved. I thought to myself, this would probably be an ideal material for use in dental applications. I began reading the clinical research and test cases regarding sinus augmentations and alveolar ridge augmentations. I was waiting for an ideal resorption case to use the INFUSE product.

Prior to rhBMP-2 developing a new “gold standard” for sinus augmentation, the industry standard was autologous bone harvested from the hip or, more recently, the tibia. The surgery to harvest the bone frequently required hospitalization, general anesthesia and it was a very costly operation, in addition to the sinus augmentation. Moreover, harvesting autologous bone also has inherent risks associated with the procedure. Being able to achieve the same results without the added risk and cost of harvesting autologous bone is a huge advantage for the patient and the doctor.

I have been performing sinus augmentations for over a decade, and I

**I** have been performing sinus augmentations for over a decade, and I always sought to use the best materials at my disposal to achieve optimal results. These results are critical in a sinus augmentation since it significantly increases the success rate of the procedures and minimizes the failure rate of the dental implant.



(Figure c:) Post-op reconstructive CT scan of implants

always sought to use the best materials at my disposal to achieve optimal results. These results are critical in a sinus augmentation since it significantly increases the success rate of the procedures and minimizes the failure rate of the dental implant.

I then decided the patient would undergo a conventional approach through a buccal window with elevation of the sinus membrane. The INFUSE collagen sponges were mixed with demineralized, freeze-dried bone in a layered “lasagna” type of configuration. The mucoperiosteal flap was closed over the opening of the sinus, which completed this first stage of the process. The patient needed to do some extensive traveling in the upcoming weeks and

months following surgery. Nine months later, the patient returned for his follow-up appointment to have the dental implants placed.

At the same time, I took a post-operative CT scan which indicated remarkable density and volume of the new bone formation. These results were very gratifying and helped to validate the use of the INFUSE Bone Graft for advanced bone resorption cases.

When placing three 5mm-in-diameter implants from Lifecore Dental, I encountered very dense and vascular bone, confirming what the CT scan had so clearly indicated prior to the implant placement. After placing the three implants, a final postoperative scan was taken (see Figure C).

This result can best be categorized as the quality and quantity of bone similar to anterior maxillary bone found in a healthy young adult. The quality and quantity of the newly generated bone far exceeded my expectations.

Contact Dr. Andrei Mark at Central Park Oral Surgery at [amark@cpoms.com](mailto:amark@cpoms.com) or by phone at (212) 813-0707. ■